

CASE REPORT

Acute otitis media and Covid-19 symptoms: a case report

Fatemeh Moghadasi Boroujeni^{1*}, Mehdi Ghadiri², Farzaneh Saberi³, Hamed Hashemi-Dezaki^{4,5}

- ¹- Department of Audiology, School of Rehabilitation Sciences, Isfahan University of Medical Sciences, Isfahan, Iran
²- Otolaryngology Group, Raad Clinic, Isfahan, Iran
³- Department of Occupational Therapy, School of Rehabilitation Sciences, Isfahan University of Medical Sciences, Isfahan, Iran
⁴- Regional Innovational Center for Electrical Engineering, Faculty of Electrical Engineering, University of West Bohemia, Pilsen, Czech Republic
⁵- Department of Electrical Engineering-Power, Faculty of Electrical and Computer Engineering, University of Kashan, Kashan, Iran

Received: 1 Jun 2021, Revised: 26 Jun 2021, Accepted: 4 Jul 2021, Published: 15 Oct 2021

Abstract

Background: In December 2019, the first Coronavirus disease 2019 (Covid-19) case was observed in Wuhan, China, and afterward, the world has been exposed to an ongoing pandemic. The Covid-19 has different symptoms, such as fever, coughing, shortness of breath, muscular pain, headache, diarrhea, nose running, and a sore throat. However, the symptoms of Covid-19 are not limited to these ones.

The Case: The present study reports a 39-year-old female patient complaining of earache and hearing loss with no other Covid-19 symptoms. The medical tests and diagnoses finally inferred that she was suffering from the Covid-19.

Conclusion: In addition to the common symptoms of Covid 19, acute otitis media can be considered as another symptom of this disease.

Keywords: Acute otitis media; Covid-19; conductive hearing loss

Citation: Moghadasi Boroujeni F, Ghadiri M, Saberi F, Hashemi-Dezaki H. Acute otitis media

and Covid-19 symptoms: a case report. *Aud Vestib Res.* 2021;30(4):306-8.

Introduction

The Covid-19 has been prevailing in the world since December 2019 [1,2]. This disease is caused by severe acute respiratory SARS-Cov-2 syndrome, presenting significant challenges and threats to the world's public health [3]. The first Covid-19 case in Iran was observed on 19 February 2020 [4]. In April 2021, Iran experienced the fourth Covid-19 peak. The Covid-19 has different symptoms, such as fever, coughing, shortness of breath, muscular pain, headache, diarrhea, nose running, and a sore throat [5,6]. However, the symptoms of Covid-19 are not limited to these ones.

Reports of several cases with conductive or sensorineural hearing loss along with/without the Covid-19 symptoms have been published in the available reports, such as [7]. A case of a woman with Covid-19 and otitis media visiting our clinic in Isfahan, Iran, is reported here.

Case presentation

A 39-year-old woman visited our clinic in Isfahan, Iran. She complained of pain, a sense of fullness, and hearing loss in her left ear for one week. In the otolaryngology examinations,

* **Corresponding author:** Department of Audiology, School of Rehabilitation Sciences, Isfahan University of Medical Sciences, Hezar Jerib St., Isfahan, 8174673461, Iran. Tel: 009831-37925044, E-mail: fmoghadasi@rehab.mui.ac.ir

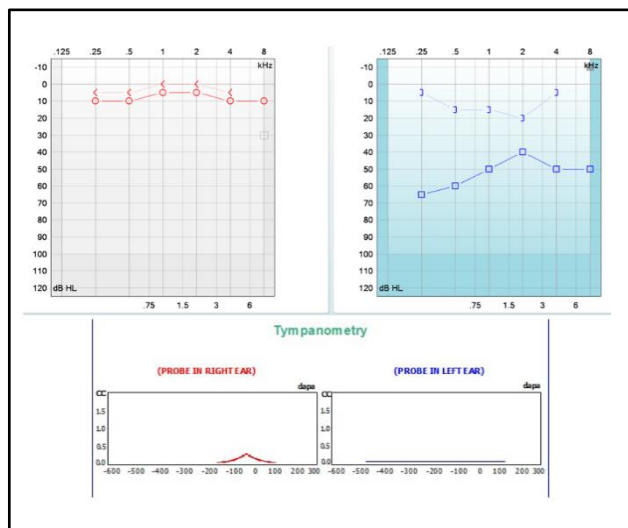


Fig. 1. The patient's audiogram and tympanogram in the first visit (a week after the beginning of symptoms).

redness and tympanic membrane bulging were observed. In the tympanometry test, type B with normal external canal volume and Type An were observed in the left and right ear, respectively. No reflex was seen in the left ear. Pure tone audiometry showed normal thresholds in the right ear but the left one was reported with mild to moderately severe conductive hearing loss (Fig. 1). Because of the current Covid-19 pandemic condition, the polymerase chain reaction (PCR) test was performed with oropharyngeal and nasopharyngeal swabs. The result was positive, while the patient had no underlying disease, and no sign of pulmonary involvement was seen. To observe the hygienic protocols, the patient was quarantined for two weeks, and her treatments were pursued at home. The patient underwent medical treatment for otitis media. After two weeks, the patient visited our clinic again. Although the patient no longer was suffering from earache, she complained about the hearing loss and sense of fullness in her left ear. In the left ear hearing tests, type B tympanometry was still present. Furthermore, slight to moderate conductive hearing loss was observed in the pure tone audiometry test (Fig. 2). Drug treatment was performed for the patient again.

In her next visit around one month later, the

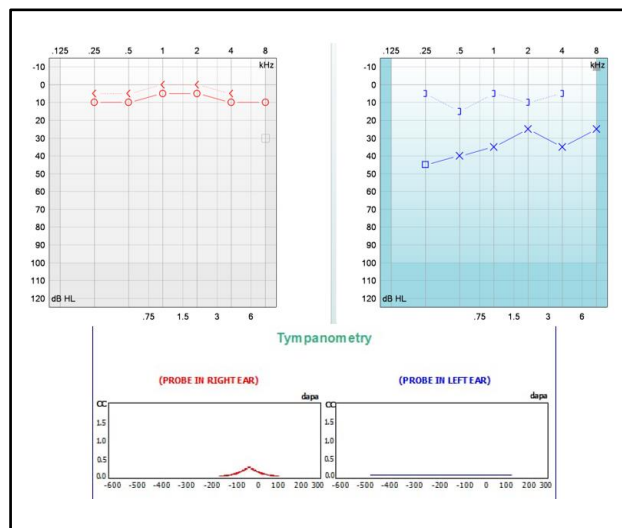


Fig. 2. The patient's audiogram and tympanogram two weeks after the first visit.

results of hearing tests of both ears showed type A tympanometry and normal auditory thresholds (Fig. 3).

Discussion

In this report, a patient complaining of earache and hearing loss visited our clinic in Isfahan, Iran and acute otitis media was observed. Meanwhile the PCR test indicated that the patient was suffering from the Covid-19. The significant point in this case, was that the patient did not display the common Covid-19 symptoms and her illness began to appear as acute otitis media.

In available case reports in Covid-19 cases, viral infections of the upper respiratory tract have been considered to be a cause of otitis media [8]. Indeed, Coronavirus has been identified as a known cause of upper respiratory tract infections, and the otitis media has been reported in several cases [3,7].

The persistent type B tympanometry in left ear can be ascribed to the prolongation of patient's nasopharyngeal and Eustachian tube tissues' edema due to some possible disorders in the mucociliary and immune system performance caused by the Covid-19. This produces negative pressure, and makes the middle ear susceptible to secondary viral and bacterial infection [7].

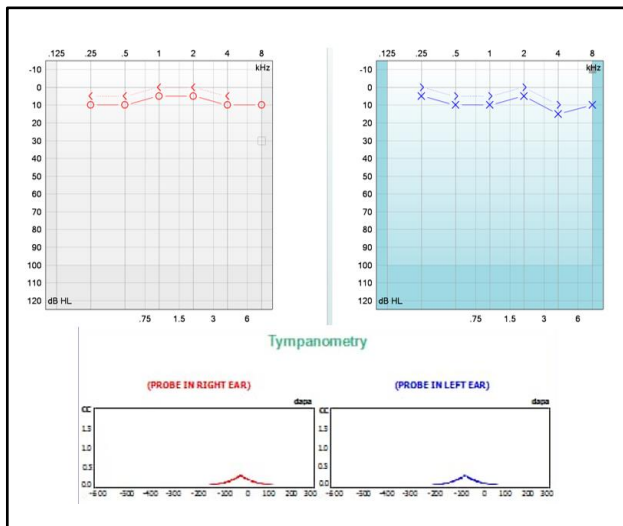


Fig. 3. The patient's audiogram and tympanogram almost two months after the beginning of her disease with normal hearing in both ears.

Conclusion

Since the only observed symptom in this Covid-19 case was earache along with a sense of hearing loss, such symptoms must be remembered as one of the possible Covid-19 symptoms. By early identifying the Covid-19 cases based on acute otitis media, a faster diagnosis could be achieved. Hence, the health of both healthcare personnel and the patient could be preserved according to the hygienic protocols.

Acknowledgments

We sincerely thank the patient who participated

in this study and allowed us to use her test results to present in this case report.

Conflict of interest

The authors declare no conflict of interest.

References

1. Jamshidi MB, Lalbakhsh A, Talla J, Peroutka Z, Hadji-looei F, Lalbakhsh P, et al. Artificial intelligence and COVID-19: deep learning approaches for diagnosis and treatment, IEEE Access; 2020;8:109581-95. doi: [10.1109/ACCESS.2020.3001973](https://doi.org/10.1109/ACCESS.2020.3001973)
2. Jamshidi MB, Lalbakhsh A, Talla J, Peroutka Z, Roshani S, Matousek V, et al. Deep learning techniques and COVID-19 drug discovery: fundamentals, state-of-the-art and future directions. *Emerging Technologies During the Era of COVID-19 Pandemic*. 2021;348:9-31. doi: [10.1007/978-3-030-67716-9_2](https://doi.org/10.1007/978-3-030-67716-9_2)
3. Fidan V. New type of corona virus induced acute otitis media in adult. *Am J Otolaryngol*. 2020;41(3):102487. doi: [10.1016/j.amjoto.2020.102487](https://doi.org/10.1016/j.amjoto.2020.102487)
4. Dodangeh M, Dodangeh M, Joulani MA, Elahian Boroujeni A. What we know about 2019-nCoV in Iran in the early stage? *Virusdisease*. 2020;31(3):1-3. doi: [10.1007/s13337-020-00596-w](https://doi.org/10.1007/s13337-020-00596-w)
5. Abdel Rhman S, Abdel Wahid A. COVID -19 and sudden sensorineural hearing loss, a case report. *Otolaryngology Case Reports*. 2020;16:100198.doi: [10.1016/j.xocr.2020.100198](https://doi.org/10.1016/j.xocr.2020.100198)
6. Chen N, Zhou M, Dong X, QU J, Gong F, Han Y, et al. Epidemiological and clinical characteristics of 99 cases of 2019 novel coronavirus pneumonia in Wuhan, China: a descriptive study. *Lancet*. 2020;395(10223):507-13. doi: [10.1016/S0140-6736\(20\)30211-7](https://doi.org/10.1016/S0140-6736(20)30211-7)
7. Raad N, Ghorbani J, Mikaniki N, Haseli S, Karimi-Galougahi M. Otitis media in coronavirus disease 2019: a case series. *J Laryngol Otol*. 2021;135(1):10-3. doi: [10.1017/S0022215120002741](https://doi.org/10.1017/S0022215120002741)
8. Maharaj S, Bello Alvarez M, Mungul S, Hari K. Otologic dysfunction in patients with COVID-19: A systematic review. *Laryngoscope Investig Otolaryngol*. 2020;5(6): 1192-6. doi: [10.1002/lio2.498](https://doi.org/10.1002/lio2.498)